

CASE REPORT

***Staphylococcus epidermidis* Necrotizing Pneumonia and Pneumatocele in a Term Infant**

Johan AJ¹, Cheah FC²

¹Department of Paediatrics, Hospital Serdang, Universiti Putra Malaysia

²Department of Paediatrics, Universiti Kebangsaan Malaysia Medical Centre

ABSTRAK

Staphylococcus epidermidis adalah satu daripada patogen yang semakin penting dalam hos yang terimunokompromi. Kami melaporkan di sini suatu kes pneumonia bernekrosis akibat *S. epidermidis* yang dikomplikasi dengan pneumatosel pada seorang bayi lelaki yang dilahir cukup bulan. Beliau menghadapi penyakit fistula trakeoesofagus yang perlu dibedah sebelum kejadian ini. Rawatan dengan antibiotik "teicoplanin" dan "gentamicin" diberikan selama empat minggu diikuti dengan "erythromycin" untuk dua minggu. Bayi tersebut tidak perlu menjalani aspirasi perkutaneus ataupun penyaliran pleura dan ianya pulih sepenuhnya dari segi klinikal dan gambaran radiologi apabila ditemu enam bulan kemudiannya semasa lawatan tindaksusulan. Rawatan dengan ubatan antimikrobial yang agresif mampu menjana pemulihan sepenuhnya tanpa mengakibatkan kerumitan dengan komplikasi seperti pneumotoraks dan fistula bronkopleura.

Kata kunci: stafilokokus tanpa enzim koagulasi, pneumonia bernekrosis, pneumatosil, *Staphylococcus epidermidis*, bayi cukup bulan

ABSTRACT

Staphylococcus epidermidis is emerging as an increasingly important pathogen in the immunocompromised host. We report here a case of *S. epidermidis* necrotizing pneumonia complicated by pneumatoceles in a term male infant who had earlier undergone surgical repair of tracheo-esophageal fistula. He was treated with intravenous teicoplanin and gentamicin for four weeks followed by two weeks of erythromycin. No percutaneous aspiration or pleural drainage was required. He had complete clinical and radiologic recovery when seen at follow-up six months later. Aggressive antimicrobial therapy for this condition without surgical drainage resulted in complete resolution and avoided complications such as pneumothorax and bronchopleural fistula.

Key words: coagulase negative staphylococcus, necrotizing pneumonia, pneumatocele, *Staphylococcus epidermidis*, term infant

Address for correspondence and reprint requests: Professor Dr. Cheah Fook Choe, Department of Paediatrics, Universiti Kebangsaan Malaysia Medical Centre, Jalan Yaacob Latif, Bandar Tun Razak, 56000 Cheras, Kuala Lumpur. Tel: 603-9145 5391. Fax: 603-9173 7827. Email: cheahfc@ppukm.ukm.my

INTRODUCTION

Staphylococcus epidermidis (coagulase negative staphylococcus) is emerging as an increasingly important pathogen in the immunocompromised host. *S. epidermidis* has been isolated as an etiological agent in critical and life-threatening conditions such as septicemia in preterm infants (von Eiff et al. 2001). We report here a case of necrotizing pneumonia, rarely attributed to *S. epidermidis* in a term infant who had earlier undergone surgical repair of tracheo-esophageal fistula.

CASE REPORT

A three-day old term male infant underwent end-to-end anastomosis and fistulectomy for esophageal atresia and tracheo-esophageal fistula. Two days post-operatively, he was extubated, but developed stridor and significant respiratory distress requiring re-ventilation. Several attempts at extubation failed; hence a bronchoscopic examination was performed at day 10, which revealed significant edema at the fistulectomy site (level of the third thoracic vertebra). He was commenced on a tapering course of dexamethasone therapy over five days to facilitate extubation. However, on day 15 of life, he had evidence of sepsis and increased oxygen and ventilatory requirements. He was febrile (temperature of 38° Celsius) and there were coarse crepitations on auscultation of both lung fields. A full blood count showed low total white cell number (1.4×10^9 /L) with neutropenia (0.9×10^9 /L) and thrombocytopenia (93×10^9 /L). Serum C-reactive protein (CRP) was also elevated (21 mg/dL). A chest radiograph showed haziness of the right lung and multiple rounded radiolucent foci with no air-fluid levels (Figure 1). Ultrasonographic examination of the lungs confirmed areas of

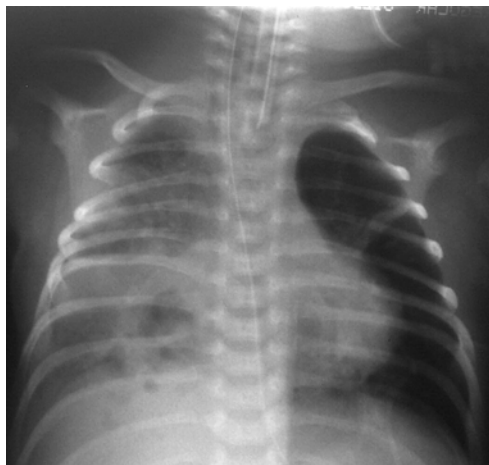

Figure 1 : Necrotizing pneumonia. Chest radiograph showing features of consolidation and multiple areas of radiolucent foci without air-fluid levels in the right lung.

consolidation but there was no evidence of abscess or empyema formation. A gastrograffin contrast study did not reveal evidence of an anastomotic leak. Cultures of blood, tracheal aspirates and the tip of the extra-pleural chest tube inserted intra-operatively grew coagulase negative *S. epidermidis*. A diagnosis of *S. epidermidis* necrotizing pneumonia with septicemia was made and he was treated with intravenous teicoplanin and gentamicin for four weeks followed by two weeks of erythromycin. No percutaneous aspiration or pleural drainage was required. A repeat chest radiograph after the first three weeks of treatment showed pneumatocele formation with some clearance of the pneumonia (Figure 2). The infant was successfully extubated from mechanical ventilation to a brief period of continuous positive air-way pressure support followed by nasal oxygen supplementation. The course of his hospital stay was not complicated by pneumothorax or bronchopleural fistula. The infant was discharged well after six weeks of antimicrobial therapy. Complete radiographic resolution of the pneumatoceles was seen on follow-up six months later.

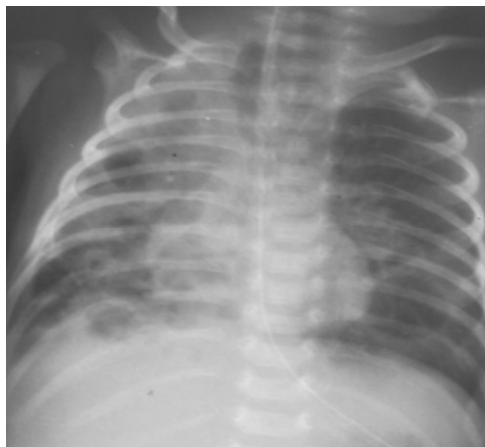


Figure 2 : Chest radiograph after three weeks of antimicrobial therapy for *S. epidermidis* necrotizing pneumonia, showing pneumatoceles in the right lung

DISCUSSION

Necrotizing pneumonia or pulmonary gangrene is a severe complication of bacterial pneumonia. More commonly reported in adults, this condition is rare in children and even more so among neonates. Organisms causing this cavitating form of pneumonia include *Streptococcus pneumoniae*, *Streptococcus pyogenes*, *Mycoplasma pneumoniae* (Hacimustafaoglu et al. 2004), *Pseudomonas aeruginosa* (Reich 1993) and methicillin-resistant *Staphylococcus aureus* (McAdams et al. 2005). An exaggerated inflammatory response is present as evidenced by raised markers of inflammation such as CRP. The mortality rate has been reported to be as high as 5.5% (Hacimustafaoglu et al. 2004). Unlike lung abscess, which is usually a solitary cavity showing rim enhancement and an air-fluid level on plain radiography or CT scan, necrotizing pneumonia manifests as multiple radiolucent foci (air crescent sign) that may be replaced by pneumatoceles after the pneumonia (Hoffer et al. 1999). The underlying pathological pro-

cess involves ischemic necrosis due to vascular invasion by the organism with endarteritis causing nonviable or gangrenous lung tissue to separate from the parenchyma (Reich 1993), creating rims of lucency (Yella et al. 2005) and subsequently pneumatoceles as radiological findings (Hacimustafaoglu et al. 2004).

This is the first reported case of necrotizing pneumonia caused by *S. epidermidis* in a neonate. We speculate that the invasiveness of this organism was heightened by the presence of risk factors such as an extrapleural catheter and the institution of steroid therapy. Early recognition of necrotizing pneumonia in a high risk infant presenting with cavitating lung lesions is important for rapid institution of optimal therapy to achieve a favorable outcome. In this case, aggressive antimicrobial therapy as conservative management instead of invasive percutaneous aspiration or drainage, resulted in complete resolution and avoided complications such as pneumothorax and bronchopleural fistula.

REFERENCES

- Hacimustafaoglu, M., Celebi, S., Sarimehmet, H., Gurpinar, A. & Ercan, I. 2004. Necrotizing pneumonia in children. *Acta Paediatr* **93**: 1172-1177.
- Hoffer, F.A., Bloom, D.A., Colin, A.A. & Fishman, S.J. 1999. Lung abscess versus necrotizing pneumonia: implications for interventional therapy. *Pediatr Radiol* **29**: 87-91.
- McAdams, R.M., Mazuchowski, E., Ellis, M.W. & Rajnik, M. 2005. Necrotizing staphylococcal pneumonia in a neonate. *J Perinatol* **25**: 677-679.
- Reich, J.M. 1993. Pulmonary gangrene and the air crescent sign. *Thorax* **48**:70-74.
- von Eiff, C., Proctor, R.A. & Peters, G. 2001. Coagulase-negative staphylococci. Pathogens have major role in nosocomial infections. *Postgrad Med* **110**: 63-64, 69-70, 73-76.
- Yella, L.K., Krishnan, P. & Gillego, V. 2005. The air crescent sign: A clue to the etiology of chronic necrotizing pneumonia. *Chest* **127**: 395-397.